Acknowledgements

The Authors would like to thank Three Counties Equine Hospital, Dr Sue Dyson, Tim Beauregard and Professor Roger K Smith

Therapy Review

The treatment of suspensory ligament desmitis

D.R. Mountford, J. Schaffer

VetCell Bioscience Ltd, Mulberry House, Fordham CB7 5LQ; and VetCell Bioscience Inc., Fort Lauderdale, Florida

Introduction

The suspensory ligament (or musculus interosseous medius) is the major supporter of the metacarpophalangeal (MCP) and metatarsophalangeal (MTP) joints. It originates from the palmer/ planter aspect of the proximal metacarpus/ metatarsus and inserts via two branches onto the abaxial surface of the proximal sesamoid bones. This 'suspensory apparatus' of the MCP/MTP joint continues distally as the distal sesamoidean ligaments. The suspensory ligament is divided into three equal thirds by reason of its anatomical features and the nature of its injuries: proximal, body and branches respectively. This so-called ligament is derived from the interosseous muscle and, in deference to its ancestry, retains some muscle tissue within its substance. This tissue is restricted to the proximal part and the body of the ligament and its function is unclear although it may serve to dampen high frequency impact forces (Wilson et al., 2001). Histologically, however, this structure most resembles a ligament, with lines of cigar-shaped cell nuclei between the linearly arranged collagen fibres.

Injuries

Injury to this structure is most common in the sports horse and its incidence increases with age.

Proximal Suspensory Disease

Proximal suspensory desmitis has become a commonly diagnosed cause of both forelimb and hindlimb lameness in recent years. It is frequently, though not always, associated with a straight hock and hyperextended MCP/MTP joint. When diagnosing this condition the response to analgesia of the deep branch of the lateral palmar/plantar site should be compared with the response to a low 4/6 point to rule out distal limb pain.

Ultrasonographically there is overlap between normal anatomical variants and pathological lesions. This can make it very difficult to be certain of the presence of lesions on ultrasound alone. When, however, there is generalised enlargement and hypoechogenicity compared to the contralateral limb, this is usually diagnostic (Figs. 1 & 2). More subtle abnormalities include focal hypoechoic areas and an indistinct dorsal border with obliteration of the normal 'gap' between the dorsal border of the ligament and the underlying bone surface. Longitudinal views can help in identifying enthesious new bone at the origin of the ligament which is associated, at least when observed radiographically, with a poorer prognosis in hindlimb cases. Care should be taken to avoid confusing enthesious new bone with callus surrounding a palmar cortical fracture (usually only seen in forelimbs). This stress fracture of the metacarpus is unrelated to the suspensory ligament and the ligament should have a normal appearance in these cases in contrast to when enthesious new bone is present.

There are stark differences in the prognosis for fore and hindlimb proximal suspensory desmitis. Acute forelimb proximal suspensory ligament desmitis carries a good prognosis with ~90% horses retuning to work following conservative management (Dyson 2000). The figures for chronic (with lameness of more than three months duration) forelimb proximal suspensory desmitis are more uncertain. For the hindlimb equivalent, the prognosis for acute desmitis is much worse (13% sound and in full work at six months; Dyson 1994), with the prognosis for chronic hindlimb cases approaching 0%.

Treatment options include initial box-rest with walking exercise for three months, followed by an ascending exercise regime. Refractory cases have been treated with extracorporeal shock wave therapy with reported significant improvements in prognosis in chronic hindlimb cases. Local neurectomy and fasciotomy has also been used in non-responsive hindlimbs. The use of mesenchymal stem cells or platelet rich plasma in chronic proximal desmitis of the forelimb has been reported to show improvement in outcome although this technique has yet to be fully evaluated.

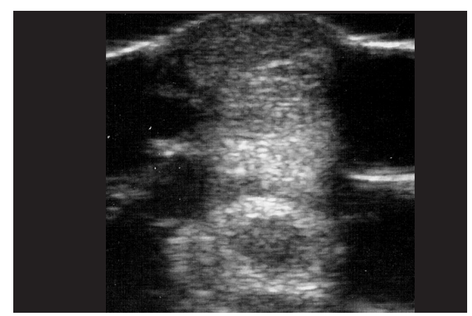

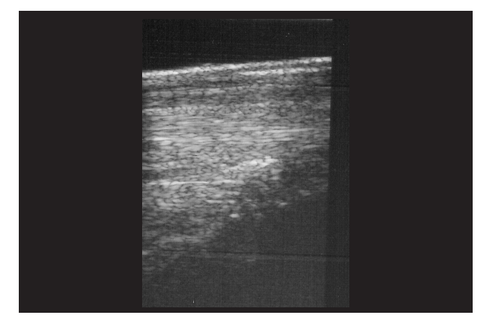

Fig. 1 & Fig. 2 Transverse and longitudinal ultrasonographs from the proximal metacarpal region, showing a large hypoechoic region in the proximal suspensory ligament, characteristic of severe proximal desmitis.

Treatment and prognosis of body and branch injuries

Lesions of the body of the suspensory ligament are rare in sports horses, where pathology of the body of the suspensory ligament usually arises from proximal extensions of branch injuries. Isolated lesions are more common in racehorses. Ultrasonographic pathology varies from focal lesions to the more common enlargement and generalised hypoechogenicity. (Fig. 3)

Unlike tendon injuries, where healing tends to occur with intratendinous fibrosis, the suspensory ligament appears to heal with both intra and periligamentar fibrosis. When imaging the branches from the medial and lateral aspects of the limb, this periligamentar fibrosis which can separate the tear-drop shaped branch from its usual position adjacent to the skin is a telltale sign of previous desmitis.

As with acute lesions in other areas of the suspensory ligament, acute branch desmitis has a variable ultrasonographic appearance although enlargement and focal hypoechogenicity are commonly seen (Figs. 4 & 5) and in some cases the lesions can extend proximally into the suspensory ligament body. As with all distal limb strain injuries, careful evaluation of the contralateral limb is important, as biaxial and bilateral injuries are common. In hindlimbs, a progressive degenerative desmitis can precede acute clinical desmitis, or may be unrelated to lameness. Thus, the contralateral limb may have enlarged, though homogenous, branches without any history of previous desmitis.

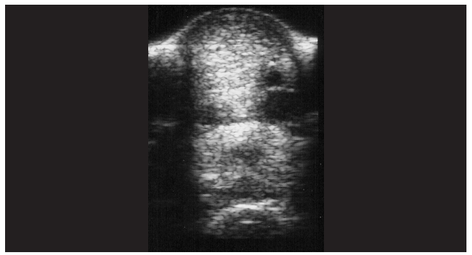

Fig.3 (above) Transverse ultrasonograph from the mid-metacarpal region (level 3(2A)) in a horse with desmitis of the body of the suspensory ligament, showing a large hypoechoic region.

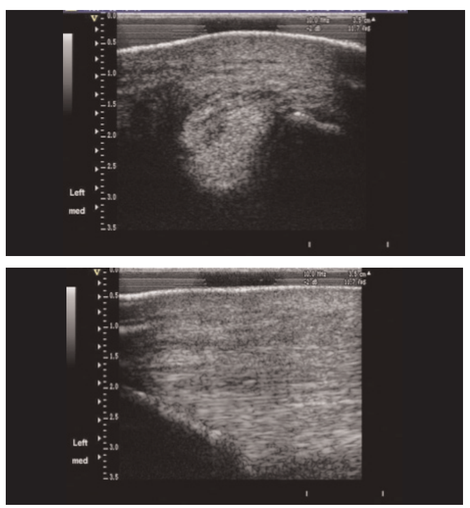

Fig.4 & Fig. 5 (left) Transverse and longitudinal ultrasonographs from the suspensory ligament branch, showing a hypoechoic region, characteristic of severe branch desmitis

Careful radiographic evaluation of the proximal sesamoid bones, splint bones and MCP/MTP joint is advised to identify concurrent bony pathology. This includes enthesious new bone and/ or abaxial avulsion fractures on the abaxial surface where the suspensory ligament branch inserts, proximal sesamoid bone fractures, distal fractures of the splint bones, and dorsoproximal proximal phalanx chip fractures in the MCP/MTP joint. This concurrent pathology is common because the initiating factor is overextension of the MCP/MTP joint. While articular fractures would require arthroscopic removal, the distal splint fractures rarely require removal.

Because of the close proximity of the joint to the suspensory ligament branch, tears in the braches can enter the MCP/MTP joint. This, together with articular fractures, may explain the common association of MCP/MTP joint pain with suspensory desmitis. Arthroscopic evaluation and debridement is indicated if such lesions are suspected.

The principle of treatment of tendon strains also applies to these injuries – namely anti-inflammatory management in the acute stages (e.g. rest, application of cold, bandaging), followed by a controlled ascending exercise with careful ultrasound monitoring in the reparative and remodelling phases. Unlike with tendon injuries where lesions usually resolve, albeit with fibrosis, persistence of ultrasonographically demonstrable abnormalities is not uncommon in the suspensory ligament.

As for proximal suspensory desmitis (forelimb), the use of autologous mesenchymal stem cells (MSC) in the treatment of suspensory ligament body and branch lesions is currently being investigated. MSC's have the potential to differentiate and to regenerate normal matrix thereby creating a functionally superior repair to fibrous scar tissue. Initial studies have included the isolation from either bone marrow or fat, followed either by direct implantation or expansion of MSC numbers in vitro before implantation. No controlled studies have been published to date to prove efficacy although anecdotal clinical evidence has been encouraging.

Along with the use of MSC's, intralesional injection of growth factors (IGF-1, TGF-ß, recombinant equine growth hormone) for the management of tendonitis, have been investigated, advocated and performed. Although similar reports for SLD are lacking, preliminary results after intralesional injection of autologous mesenchymal stem cells, bone marrow and acellular tissue components derived from porcine urinary bladder submucosa are encouraging. In human medicine, clinical application of platelet-rich-plasma (PRP) containing high levels of various growth factors has been described to augment bone, wound and ligament healing.

Recent use of platelet enriched products, such as that produced by the Acelere™ *f*PRP system has shown that PRP can be safely used in horses and represents a novel, valuable alternative and/or adjunctive treatment option in horses with suspensory ligament desmitis and may provide growth factors (PRGF and TGF-ß) that encourage healing in line with the reports in human literature. Good foot balance and the use of egg-bar shoes, or shoes with branches extending caudally behind the heels, are believed to be protective of the suspensory ligament and therefore corrective trimming and shoeing are important adjunctive therapies. ■

Case Study: Severe branch desmitis treated with Acelere™ *f*PRP system

Summary

This study presents the treatment and outcome of a suspensory branch desmitis in a thoroughbred racehorse using the Acelere™ *f*PRP system. Clinically and ultrasonographically the treatment was associated with a resolution of the lesion.

Case Details

A 7 year old thoroughbred racehorse was presented with a right forelimb lameness. On ultrasonographic examination a hypoechoic region in the medial branch of the suspensory ligament was identified, (Figs. 6 & 7) and this was established as the cause of the lameness.

Treatment

The patient was restrained and sedated with a combination of detomidine HCL and butorphanol. The affected branch area and subcarpal local anaesthetic sites were clipped and aseptically prepared. To ensure complete desensitisation a uniaxial low 4 point block was performed. Autologous platelets were harvested using the Acelere fPRP system. A total of 7.5ml of platelet solution was harvested with a total platelet count of 789 10^3 platelets/mm^3.

Using ultrasound guidance, a 23 gauge needle was inserted into the lesion and 3ml of the platelet solution was implanted directly in to the lesion. The limb was then bandaged, the horse box-rested for 7 days with 3 days routine antibiotics (intramuscular neomycin). The patient then entered an ascending rehabilitation programme.

Outcome

Following 8 weeks of walk exercise the patient was re-examined and showed no signs of lameness; ultrasonographically there appeared to be good reconstruction of the affected suspensory branch (Figs.8 & 9). The rehabilitation programme continued with a gradual increase in exercise closely monitored with ultrasonographic examination.

Discussion

A variety of local, medical and celluar therapies have been used to treat suspensory branch desmitides. There are, however, limited studies assessing the efficiency of these therapeutic options. Activated platelets release growth factors that are believed to enhance the healing response and quality of repair in the treatment of desmitis. A concentrated platelet solution produced using the Acelere™ fPRP system can deliver a high concentration of these growth factors to the injured tissues.

Implantation of Acelere™ *f*PRP system derived platelets into a core suspensory branch lesion appears to have been associated with a resolution of lameness and a significant improvement in the ultrasonographic appearance of the injured area. This provides support for the clinical use of the Acelere™ fPRP system in the treatment of these injuries. ■

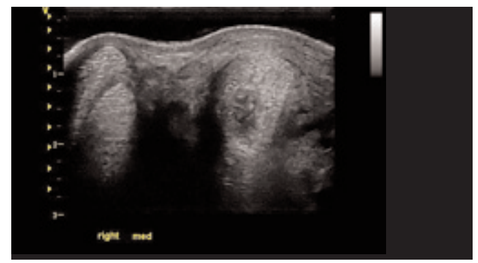

Fig.6 Transverse ultrasonograph of the affected branch

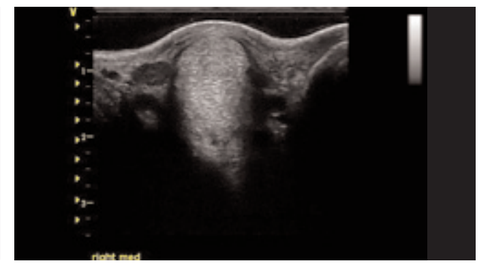

Fig .8 Transverse ultrasonograph of the affected branch 8 weeks post treatment with Acelere fPRP system

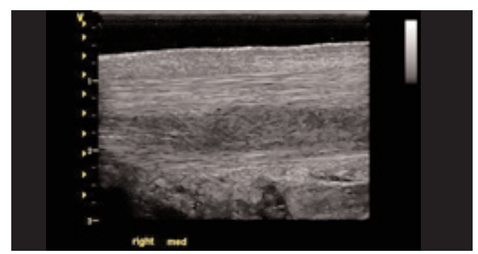

Fig. 7 Longitudinal ultrasonograph of the affected branch

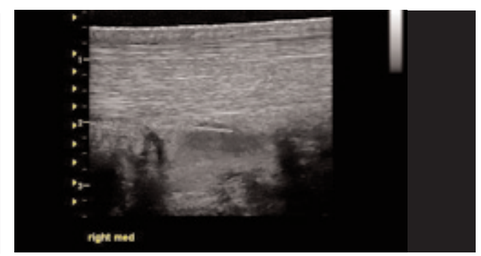

Fig. 9 Longitudinal ultrasonograph of the affected branch 8 weeks post treatment with Acelere fPRP system

Further reading

Preparation & Application of Platelet-enriched Plasma. Dr Alan Nixon

Platelet Rich Plasma Enhances (PRP) Anabolic Gene Expressions Patterns in Flexor Digiorum Superficalis Tendons. Lauren V Schnabel[1], Hussni O. Mohammed[2], Brian J. Miller[1], William G. McDermott[1], May S. Jacobson[3], Kelly S Santangelo[1], Lisa Fortier[1].

[1] Department of Clinical Sciences, VMC C3-181, Cornell University, Ithaca, New York, 14853

[2] Department of Population Medicine & Diagnostic Sciences, Cornell University, Ithaca, New York, 14853

[3] Blood Preservation Laboratory, Children's Hospital, Boston, Massachusetts, 02115

Anabolic effects of acellular bone marrow, platelet rich plasma, and serum on equine suspensory ligament fibroblasts in vitro. Smith JJ, Ross MW, Smith RK.

Platelet-rich plasma gel promotes differentiation and regeneration during equine wound healing. Carter CA, Jolly DG, Worden CE Sr, Hendren